

---

---

## An Unusual Cause of Variceal GI Bleed

Viswanath Reddy<sup>1</sup>, G.R. Srinivas Rao<sup>2</sup>, Jagadeeswar Goud G.<sup>3</sup>, Milap Shah<sup>4</sup>

**Author Affiliation:** <sup>1,2</sup>Consultant Gastroenterologist, <sup>3</sup>Consultant Surgical Oncologist, <sup>4</sup>Consultant Pathologist, Yashoda Hospital, Secunderabad, Telangana 500003, India.

**Reprint Request:** D. Viswanath Reddy, Consultant Gastroenterologist, Department of Gastroenterology, Yashoda Hospital, Secunderabad, Telangana 500003, India.  
E-mail: viswanathdr@yahoo.com

---

### Abstract

*Background:* Mesenteric vein thrombosis due to Mesenteric fibromatosis presenting with ectopic variceal bleed is less common. *Case Description:* 38 year old male presented with history of large volume melena. He was resuscitated and Endoscopy was done, showed multiple ectopic varices-bleeder in Duodenal third portion, hemostasis achieved by injecting Cyanocrylate glue. On reviewing, he had evaluation for pain abdomen, a year back which suggested inoperable retroperitoneal neoplasm. He had taken alternative medicine, being given a poor prognosis. Endosonography guided aspiration from lesion was suggestive of atypical cells. After 1 year, he had re-bleeding. Glue injection was done to another bleeding varix in D3. Repeat CT scan showed similar sized retroperitoneal mass. Diagnostic laparoscopy showed Omental cake like mass, histologically - mesenteric fibromatosis. *Clinical Relevance:* GI Bleed is a rare manifestation of Mesenteric fibromatosis and here it was variceal bleed secondary to thrombosis of the mesenteric vein, managed endoscopically. Patient had spontaneous Mesenteric fibromatosis and is stable for few years now. Hence, all retroperitoneal lesions need complete evaluation before giving a poor prognosis.

**Keywords:** Mesenteric Fibromatosis; Retroperitoneal Mass; Ectopic Variceal GI Bleeding; Glue Injection; CT abdomen; Endosonography; Diagnostic Laparoscopy; Histopathology.

---

### Introduction

Mesenteric fibromatosis, also known as mesenteric desmoids, is part of the clinical-pathologic spectrum of deep fibromatosis, which encompasses a group of benign fibro-proliferative processes that are locally aggressive and have the capacity to infiltrate or recur without metastasis. It is classified according to their anatomical location, whether it is intra-abdominal, from the deep soft tissues of the abdominal wall, or deep within the extra-abdominal soft tissues. It usually affects females and in fourth decade of life. They present with pain abdomen, bloating, weight loss or abdominal mass. It is associated with abdominal trauma,

surgery or could be spontaneous. Gardner's syndrome is associated in few of them.

Surgery is definitive management. Chemotherapy is an alternative option. Radiation may be given in selected cases.

We hereby describe a patient whose presentation was unusual as it is less common in males, there was no associated Gardner's syndrome, nor any abdominal surgery nor trauma, but was detected on evaluation of gastrointestinal bleeding. Ectopic variceal bleeding due to thrombosis of Superior Mesenteric Vein due to infiltration from Mesenteric fibromatosis is rare. All retroperitoneal mass lesion patients need complete evaluation before giving a poor prognosis.

**Case Report**

A 38 year old male, was referred with history of black and maroon coloured stools for 5 days, requiring multiple blood transfusions. Endoscopy done elsewhere was reported normal.

Patient was stabilised with transfusions and Pantoprazole infusion.

After stabilisation, Endoscopy was done which showed multiple bunches of varices and a bleeding varix in deep duodenum (D3).

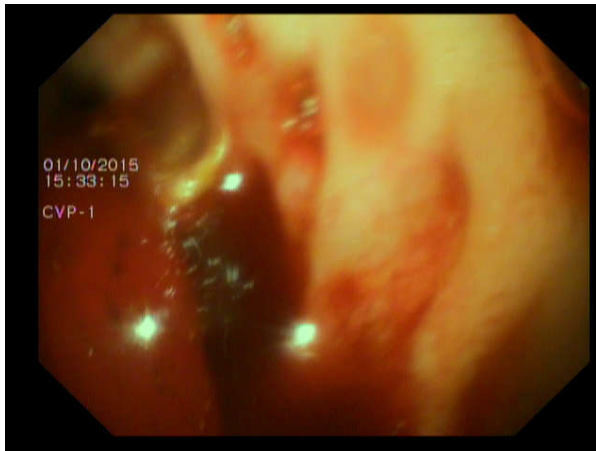

Fig. 1: Endoscopic image in D3: Blood in lumen

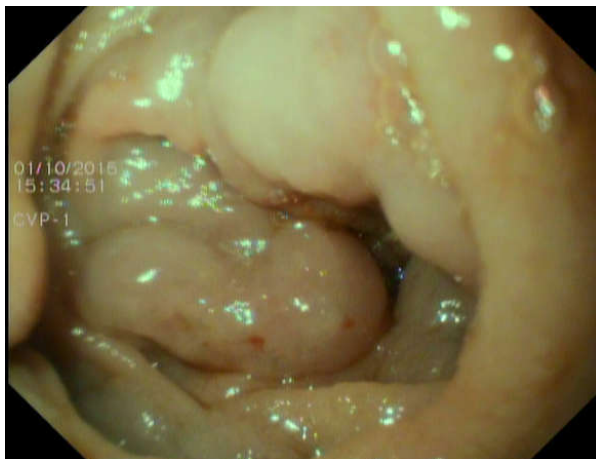

Fig. 2: Endoscopic image- Post glue injection

Two ml of Cyanocrylate glue was injected into the bleeding varix and hemostasis was achieved.

On reviewing history, patient had Episode of pain abdomen 1 year back for which he underwent evaluation elsewhere and found to have a mass in peripancreatic region. Endosonography guided fine needle aspiration was suggestive of atypical cells. Contrast enhanced CT abdomen showed inoperable retroperitoneal mass. He had taken

alternative medicine-Tibetan medicine for the same.

CT Abdominal angiography was done which showed a poorly enhancing mass with hypodense rim of soft tissue encasing proximal SMA for a length of approximately 8 cms (3.1 x 4.0 cms in AP x Tr dimensions) with mild adjacent desmoplastic reaction- likely neoplastic. Mesentery showed increased perivascular stranding with enlarged mesenteric lymphnodes (average size 8-9 mm SAD). Splenoportal venous confluence is attenuated by the mass lesion with non-visualised SMV-? Attenuated / thrombosed. Multiple portovenous collaterals are seen in perigastric region, splenic hilum , mesentery and omentum.

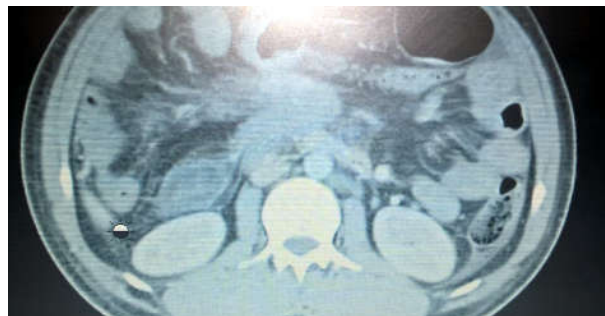

Fig. 3: CT image showing mass encasing vessels with collaterals

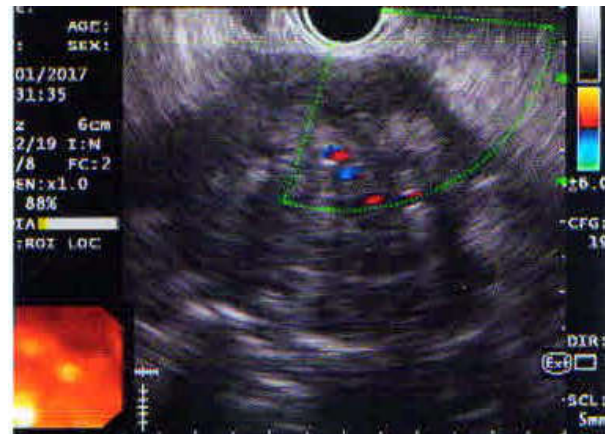

Fig. 4: EUS image of the mass lesion

Serum CEA, CA 19-9 was normal.

He was advised Endosonography guided FNA or diagnostic Laparoscopy after surgical consultation. Patient was stabilised and discharged on request on beta-blocker and hematinics.

After 3 months, patient came back for further management following another course of Tibetan medicine. EUS guided FNA was done which revealed atypical cells.

Antinuclear antibodies were negative and Immunoglobulin-IgG4 levels were within normal

range. He was advised diagnostic Laparoscopy and proceed tumour removal if feasible.

He came back after few months, Laparoscopy done which revealed omental cake like mass from which only biopsy could be taken.

Histopathology showed dense fibrosis with lymphoplasmacytic infiltration. Immunohistochemistry showed negative for lymphoma panel and mesenteric fibromatosis was diagnosed.

In view of association with Adenomatous Polyps, colonoscopy was done which was normal. There was no eye symptom.

Patient was explained about disease prognosis and limited options in view of extensive disease and vascular involvement. He was discharged on hematinics.

He came back after 6 months with another episode of bleeding.

Repeat endoscopy was done and another varix in duodenum was showing bleeding stigmata into which glue injection was done and haemostasis was achieved.

He is currently receiving beta-blocker and hematinics and doing well.

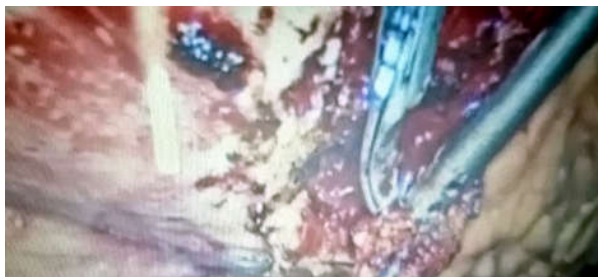

Fig. 5: Laparoscopic picture-omental cake

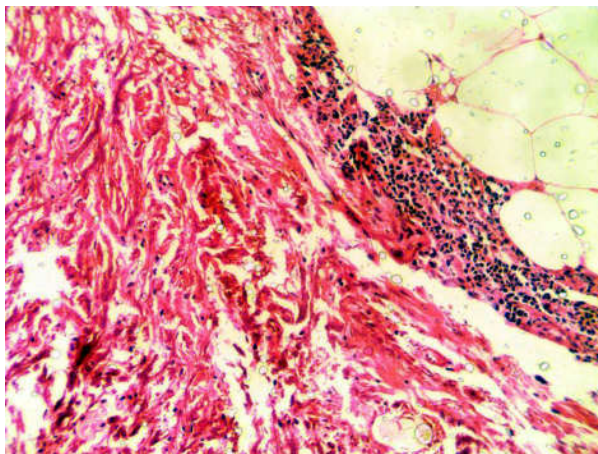


Fig. 6: Histopathology-H&E staining: Fibrosis, Collagen, chronic inflammation, no mitoses

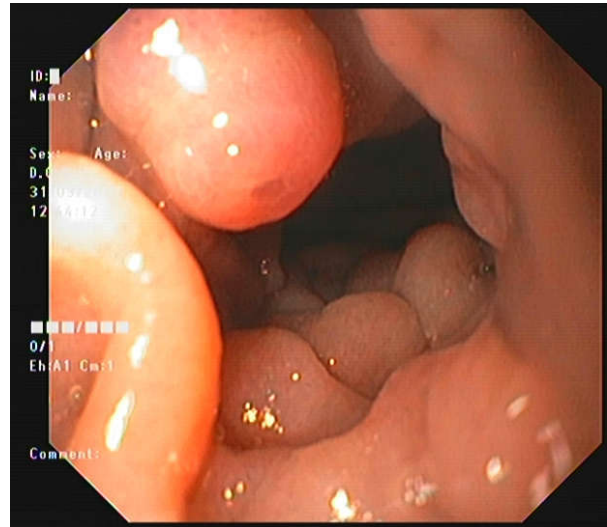


Fig. 7: Endoscopy image: Second varix with ulcer

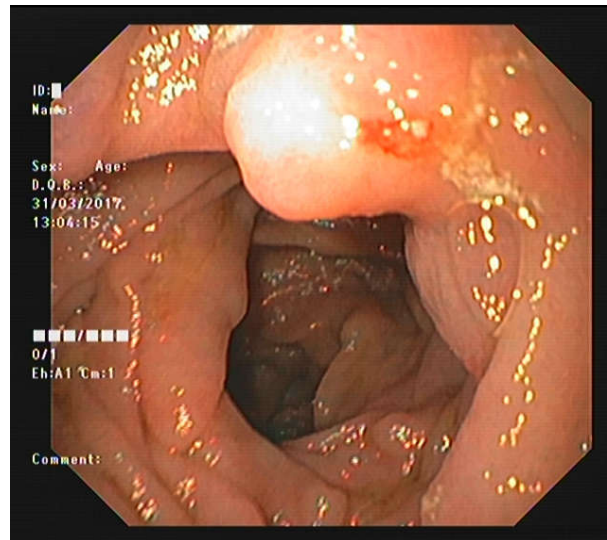


Fig. 8: Endoscopy image- Post Glue injection

Our case was unique because patient was male with no features of Gardner’s syndrome and there was no abdominal trauma or surgery. He presented with bleeding due to varices which developed following SMV thrombosis. He is surviving with good functional status after being given a bad prognosis 3 years back. Hence, all retroperitoneal lesions need complete evaluation before giving any prognosis.

### Discussion

Mesenteric fibromatosis is a fibroblastic proliferation of the mesentery due to surgical trauma or spontaneously. Most of the cases are intra-abdominal and involve mesentery, however mesenteric desmoids account for less than 10% of

sporadic desmoid tumors [1,2]. They can arise spontaneously after surgical trauma or abdominal surgery. Thirteen percent of patients with mesenteric fibromatosis have FAP, specifically the Gardner syndrome variant of FAP [1]. Therefore, patients with FAP and a family history of mesenteric desmoids have a greater than 25% chance of developing this tumor [1]. Additionally, 83% of patients with FAP and mesenteric fibromatosis have a history of abdominal surgery, most commonly a total colectomy [1]. Disease is more aggressive in patients with FAP. Mesenteric fibromatosis is more common in female patients (80%) from 14 to 75 years of age (mean: 41 years), without any preference in race [1]. The female predilection is due to the fact that estrogen, even exogenous estrogen, is a factor that predisposes one to mesenteric fibromatosis and plays a role in its formation. MF occurs more frequently during pregnancy and in premenopausal women compared to postmenopausal women [3]. The patient usually presents with signs and symptoms related to the small bowel such as abdominal pain or a palpable abdominal mass, or clinical complications like small bowel obstruction, fistula formation, or bowel perforation [1]. Gastrointestinal bleeding is rare manifestation of mesenteric fibromatosis and it occurs if it involves the wall of bowel mimicking Gastrointestinal Stromal Tumour (GIST). Immunohistochemistry can help differentiate mesenteric fibromatosis from GIST. Cd117, PDGFR, CD4 and DOG1 are positive in GIST and beta-catenin staining in mesenteric fibromatosis [13,14,15].

Although the natural course and clinical progression is not predictable, some of them remain stable for long and some regress over time.

The management of mesenteric fibromatosis includes multiple modalities. Surgical resection is definitive in non invading tumours. 53-67% of cases, it is operable [1,5]. Hormonal therapy with Tamoxifen or interferon and NSAIDS with chemotherapy can play a role in the treatment due to the fact that local recurrence is high, mainly in Gardner's syndrome patients. Doxorubicin is the preferred chemotherapy agent [5]. Post operative complications like short bowel and enterocutaneous fistula can occur. If resected incompletely, it tends to recur and are locally aggressive [5,6].

Vinblastine and Methotrexate with Tamoxifen are used if tumour recurs. Tyrosine kinase inhibitor, Imatinib is an alternative if there are multiple tumours.

Indomethacin and sulindac can be tried in

unresectable tumours. Prednisolone and Azathioprine have been shown success in case reports [6].

Radiation therapy has a small role in mesenteric fibromatosis treatment in intraabdominal Desmoids and without any involvement of vessels [5,6].

Our patient had locally advanced disease and hence not a candidate for surgery. Radiation is contra-indicated in view of vascular involvement and extensive disease. Chemotherapy was not considered after discussing with patient. He is currently receiving hematinics and beta-blockers and doing well with 3 years of follow up. Mesenteric fibromatosis could have a long term stable course and hence patients with retroperitoneal mass should be thoroughly evaluated for possible surgery or alternative modalities and followed up for disease related complications and not to be labelled as having poor prognosis.

### Conclusion

Mesenteric fibromatosis is fibroblastic proliferation affecting the mesentery after surgical trauma or spontaneously and in Familial adenomatous Polyposis. It is more common in females and is locally aggressive. Surgery, Chemotherapy and Radiation therapy are the options for management.

This case was unusual as the patient presented with recurrent ectopic variceal bleeding due to mesenteric vein thrombosis managed endoscopically. Patient is doing well with three years follow up after being labelled as inoperable retroperitoneal neoplasm. All retroperitoneal mass lesions need complete evaluation before giving a bad prognosis.

### Acknowledgements

We thank Dr. Murari for anaesthesia support for endoscopy procedure. We also thank our technicians Subhashini and Geetha for technical help during endoscopy procedure.

### References

1. R.L. Kempson, C.D. Fletcher, H.L. Evans, M.R.

- Hendrickson, and R.K. Sibley, Tumors of the Soft Tissues, Armed Forces Institute of Pathology, Washington, DC, USA, 1998.
2. Burke AP et al. Intra-abdominal fibromatosis: A pathological analysis of 130 tumours with comparison of clinical subgroups. *Am J Surg Pathol.* 1990;14:335-41.
  3. Piessen G et al. Mesenteric Panniculitis. *Annam Chir.* 2006;131:85-90.
  4. Emory TS et al. Sclerosis get Mesenteritis, Mesenteric Panniculitis and Mesenteric Lipodystrophy: A Single Entity? *Am J Surg Pathol.* 1997;21:392-98.
  5. Akram S et al. Sclerosing mesenteritis: clinical features, treatment, and outcome in ninety-two patients. *Clin Gastroenterol Hepatol.* 2007;5:589-96.
  6. Tytgat GN et al. Successful treatment of a patient with retroactive mesenteritis with prednisolone and azathioprine. *Gastroenterologist.* 1980;79:352-56.
  7. Bechade D et al. Etiologic spectrum of mesenteric Panniculitis: a report of 7 cases. *Rev Med Intern.* 2007;28:289-95.
  8. Horton KM et al. CT findings in sclerosing mesenteritis (Panniculitis): spectrum of disease. *Radio graphics.* 2003;23:1561-67.
  9. Kelly JK et al. Idiopathic retractile (sclerosing) mesenteritis and its differential diagnosis. *Am J Surg Pathol.* 1989;13:513-21.
  10. Gregory Nicolas et al. Incidental finding and management of mesenteric fibromatosis. *Am J Case Rep.* 2016;17:389-394.
  11. Abhinav M et al. Mesenteric fibromatosis presenting as a diagnostic dilemma: A rare differential diagnosis of right iliac fossa mass in an eleven year old-a rare case report. *Case Rep Surg.* 2013;2013:569578.
  12. Stoidis CN et al. Surgical treatment of giant mesenteric fibromatosis presenting as a gastrointestinal stromal tumour: A case report. *J Med Case Rep.* 2014;4:314.
  13. Ang C et al. Computed tomographic presentation of mesenteric fibromatosis. *Dig Dis Sci.* 2005;50(2): 348-50.
  14. Rodriguez JA, Guarda LA, Rosai J. Mesenteric fibromatosis with involvement of the gastrointestinal tract. A GIST simulator: A Study of 25 cases. *Am J Clin Pathol.* 2004;121(1):93-98 [PubMed].
  15. Marek Wronski et al. Mesenteric fibromatosis with intestinal involvement mimicking a gastrointestinal stromal tumour; *Radiol Oncol* 2011 Mar;45(1) 59-63.
-

## **Red Flower Publication (P) Ltd.**

*Presents its Book Publications for sale*

- |   |                      |
|---|----------------------|
| <b>1. Shipping Economics (New for 2018)</b> by D. Amutha, Ph.D.   | <b>INR345/USD27</b>  |
| <b>2. Breast Cancer: Biology, Prevention and Treatment (2015)</b><br>by Rana P. Singh, Ph.D. & A. Ramesh Rao, Ph.D. (JNU) | <b>INR395/USD100</b> |
| <b>3. Child Intelligence (2005)</b> by Rajesh Shukla, MD.   | <b>INR150/USD50</b>  |
| <b>4. Pediatric Companion (2004)</b> by Rajesh Shukla, MD.  | <b>INR250/USD50</b>  |

### **Order from**

**Red Flower Publication Pvt. Ltd.**

48/41-42, DSIDC, Pocket-II

Mayur Vihar Phase-I

Delhi - 110 091(India)

Mobile: 8130750089, Phone: 91-11-45796900, 22754205, 22756995

E-mail: sales@rfppl.co.in